
CASE REPORT**Pyogenic Granuloma in a Patient of Sturge-Weber Syndrome with Bilateral Port Wine Stain- A Rare Case Report**

Shantala Arunkumar^{1*}, Mamata G. P.², Rajeshwari G. Annigeri², Shakuntala G. K.³

¹Department of Oral Medicine and Radiology, SDM College of Dental Sciences and Hospital, Sattur, Dharwad - 580009 (Karnataka) India; ²College of Dental Sciences and Hospital, Davangere - 577004, (Karnataka) India; ³MAHE Institute of Dental Sciences & Hospital, Mahe - 673310, (Pondicherry) India.

Abstract

Sturge-Weber syndrome (SWS) also known as encephalotrigeminal angiomas. It is a neurocutaneous syndrome, characterized by a facial vascular birthmark and neurological abnormalities. An ipsilateral or bilateral facial cutaneous vascular malformation Port Wine Stain (PWS) usually affects the upper face. Other clinical manifestations are seizures, glaucoma, hemiparesis, mental retardation and delayed developmental milestones. The main objective of this case report is to unravel such a rarest syndrome with bilateral port-wine stain, which has intraoral manifestation of pyogenic granuloma involving gingiva in an 11 year old boy.

Keywords: Bilateral Port-Wine Stain, Pyogenic Granuloma, Sturge-Weber Syndrome, Vascular Malformations

Introduction

Sturge-Weber Syndrome (SWS) or encephalotrigeminal angiomas is a rare nonhereditary developmental condition. It is a sporadic neurocutaneous syndrome affecting the cephalic venous micro-vasculature. It occurs, with an estimated frequency of 1 in 50,000 live births [1]. SWS typically presents with a flat facial cutaneous vascular malformation in a neonate. The syndrome is characterized by leptomeningeal and cerebral angiomas, typically ipsilateral to the facial lesion, often accompanied by convulsions,

mental retardation, contralateral hemiparesis, hemiatrophy, homonymous hemianopia, and glaucoma. The usual cutaneous finding is a unilateral nevus flammeus [Port Wine Stain (PWS)], involving an area supplied by trigeminal nerve. The PWS varies from light pink to deep purple. The overall risk of developing SWS in a patient with any kind of cutaneous vascular malformation is approximately 8%. The lesion in SWS, typically is a few centimeters across and involves the face, scalp, and neck. It is virtually a rule that at least part of the PWS extends to the forehead and upper eyelid. Patients with the involvement of the eyelids are at a higher risk of development of eye and brain disease. In upto 40%, the facial PWS is bilateral, although not necessarily symmetrical. The facial nevus flammeus over a period of time may not remain macular, and may develop papular and verrucous changes [2].

SWS have a special meaning to oral physician due to its strong head and neck involvement and a possible manifestation in the oral cavity [3]. Many clinical aspects for SWS are published in the literature. We are reporting a case of SWS with bilateral occurrence of PWS, which also presented with pyogenic granuloma involving gingiva in the lower left premolar region.

Case Report:

An 11 year old boy, who was a diagnosed case of SWS reported to our department with swelling

over the left lower gum region since 3 months. Initially the swelling started in the left lower gum region, of peanut size and slowly progressed to the present size. Swelling was not associated with pain, ulceration or pus discharge. Patient had difficulty in mastication, closing the mouth and speaking, noticed bleeding while brushing the teeth. There was no history of difficulty in swallowing, fever or weight loss and similar swelling elsewhere in the body, or oral cavity. He was born prematurely to nonconsanguineous parents and had delayed milestones. At birth cutaneous angiomas were noted on his left and right facial region extending to neck and patient was kept under observation. Patient had first epileptic attack at the age of 8 months and once in a month till the age of 6yrs and he was on continuous treatment with low doses of sodium valproate from the time of first attack and currently on 200 mgs twice daily. At present seizures are under control and motor development has been normal, but his mental developments has been subnormal. This has been confirmed by psychological assessment reports showing IQ of 47 on Binet Kamat test of intelligence & below the average on other test indicating the cognitive deficits. Electroencephalogram reports were abnormal, suggestive of post central dysfunction, which necessitated for primary level institutionalized care. CSF analysis reports were within the normal limits. Magnetic Resonance Imaging (MRI) of brain (Fig.1) showed bilateral mild atrophy of occipital and parietal lobes right more than left with the areas of gyriform calcifications.

Post contrast images showed dense bilateral leptomeningeal enhancement involving occipital and post parietal lobes and minimal bilateral gyral enhancement suggestive of ischemic changes, paucity of cortical veins, enlargement of choroid plexus bilaterally and prominent medullary veins were seen in MRI angiography images. Ophthalmology opinion was taken, which was normal.

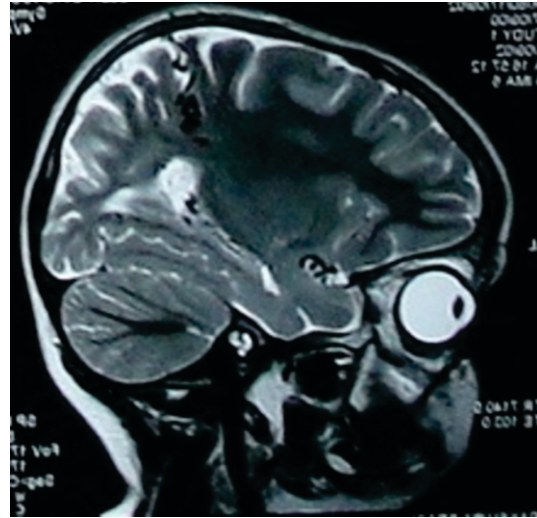


Fig. 1: MRI showing gyriform calcifications of parietal and occipital lobes

On clinical examination, patient was in a good general condition, had normal gait, was conscious, co-operative, less oriented with the time, place and as a person with normal vital signs. His face was markedly red and slightly swollen bilaterally, covering whole face including the ears and forehead with central part was spared, on left side extending to neck region suggestive of cutaneous angiomas. Hypertrophy of the upper and lower lips was seen (Fig.2).

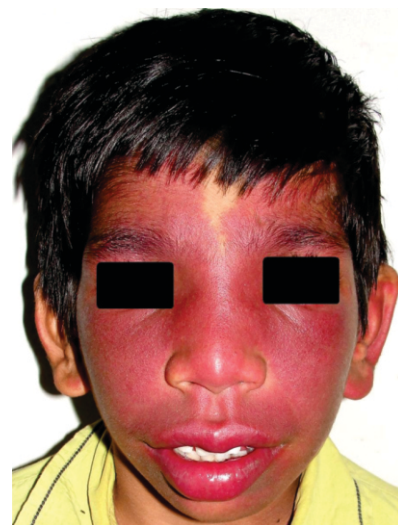

Fig. 2: Bilateral Portwine Stain over the Face and Neck

On intraoral examination, the mucosa covering the oral cavity was reddish in color with no evidence of any hypertrophy, except for a solitary, sessile, well defined swelling in the gingiva of 33, 34, & 75 covering the crowns of 33 & 34, measuring about 2x2cm in size. Anteroposteriorly extending from distal surface of 32 to the distal surface of 75, superoinferiorly from lingual gingiva by completely covering the occlusal surfaces of 33 & 34 to the buccal vestibule. Mucosa over the swelling was pale pink in color, covered with the necrotic slough; no evidence of bleeding was present. On palpation it was non-tender, soft to firm in consistency, did not bleed on palpation. So clinically, it was diagnosed as pyogenic granuloma of gingiva (Fig. 3). It was planned for excisional biopsy.

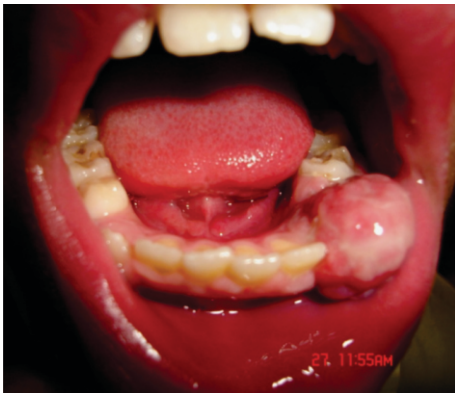

Fig. 3: Pyogenic Granuloma of Gingiva

On intraoral periapical radiography radiolucency was seen in the primary second molar suggestive of caries and bone loss present mesial to unerupted 35 & increased interdental space was seen between 33 & 34. On panoramic radiography altered trabecular pattern was seen and width of the mandible was found to be less (Fig.4). His posteroanterior & lateral skull views showed no intracranial calcifications.

Pediatric (genetic specialist) opinion was taken and patient was started on prednisolone in a tapering dosage for one week before excision of the swelling, to prevent bleeding. Later the growth was excised under conscious sedation and sent it

for histopathological investigations and was diagnosed as a pyogenic granuloma of gingiva. Postoperative period was uneventful, and no recurrence after four-years of follow up.

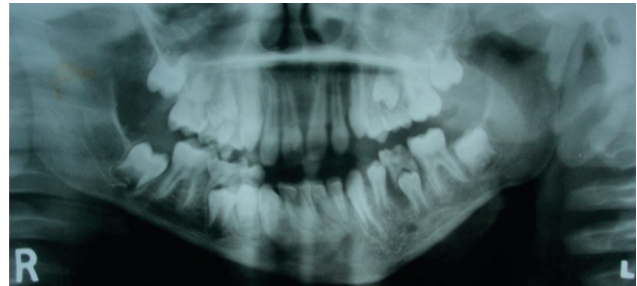


Fig. 4: Panoramic Radiograph Showing Bone Resorption From 33-35

Discussion:

SWS was first described by Schirmer in 1860 and later more specifically by Sturge in 1879, who associated dermatological and ophthalmic changes of the disease to neurologic manifestations. Weber in 1929 complemented it with the documentation of radiologic alterations where calcifications are gyriform and curvilinear and most commonly seen in parietal and occipital lobes of brain [4]. Later neurocutaneous syndrome was first discussed as a clinical entity by the ophthalmologist Van der Hoeve, who included neurofibromatosis, tuberous sclerosis, Sturge-Weber syndrome and Von Hippel-Lindau syndrome. Currently 20 to 30 disorders are grouped under the neurocutaneous syndromes [5, 6].

The SWS is thought to result from anomalous development of the primordial vascular bed during the early stages of cerebral vascularization. At this stage, the blood supply to the brain, meninges and face is undergoing reorganization while the primitive ectoderm in the region differentiates into the skin of the upper face and occipital lobe of the cerebrum. The overlying leptomeninges are richly vascularized, and the brain beneath becomes atrophic and calcified, particularly in the

molecular layer of the cortex [3]. It is presumed that interference at 5 to 8 weeks of gestation with the development of vascular drainage of these areas subsequently affects the face, eyes, leptomeninges, and brain [7]. These structures share a common embryological basis in the promesencephalic and mesencephalic neural crest, where an unknown insult results in malformations in the tissue that differentiates from it. Most common features are epilepsy (80%), dermal angiomas resulting in PWS (76%), abnormal findings in skull radiographs (63%), mental retardation (54%), ocular involvement (37%) and hemiplegia (37%) [3].

SWS is referred to as complete when both CNS and facial angiomas are present and incomplete when only one area is affected without the other. The Roach Scale is used for classification, as follows [5].

- Type I - Both facial and leptomeningeal angiomas; may have glaucoma
- Type II - Facial angioma alone (no CNS involvement); may have glaucoma
- Type III - Isolated leptomeningeal angioma; usually no glaucoma

In our case, patient had both facial and leptomeningeal angiomas, but no glaucoma, so it is SWS of type I. The facial nevus is present at birth, in 40% of case is bilateral as we see in our case. Three-fourth percent of the patients with bilateral facial hemangiomas have a tendency to extension of the hemangioma beyond the face to the neck, trunk and extremities [2]. Our patient too had facial angioma at birth, bilaterally covering the whole face, extending to neck on left side and ear.

Seizures develop in most patients during first year of life [5]. They are typically focal tonic clonic and contralateral to the side of the facial nevus. Our patient had partial seizure on left side with secondary generalization, which was developed within one year of age and he was managed symptomatically with low doses of sodium valproate.

The seizures in SWS may become refractory to anticonvulsants and are associated with a slowly progressive hemiparesis in many cases [3]. About one half of patients are mentally abnormal and have behavioral problems. As seizures of early onset increase in frequency and severity, mental functions and behavior often regress probably the result of prolonged generalized seizures and increasing cerebral atrophy. Secondary to local hypoxia and use of numerous anticonvulsants and even in our case also delayed milestones with cognitive deficits were reported.

Glaucoma and bupthalamos (hydrophthalmia), enlargement of the eye occurs from the same mechanisms as glaucoma of the ipsilateral eye are a common complication and but not a consistent feature [8]. The ophthalmic examination of our patient did not reveal any abnormalities.

The radiographic hallmark of SWS is “tram-line” or gyriform calcifications usually involving the occipital and parietal lobes is seen in plain skull radiographs usually demonstrate intracranial calcification that have a serpentine linear, parallel configuration (tram sign) primarily in the occipital or parieto-occipital regions in about 90% of patients [9]. Our patient's skull radiographs were normal, but minute changes were highlighted in MRI brain. This is probably because the changes appear usually by the second decade. The intraoral PWS may remain macular or may proliferate to become papular or verrucous growth. Many cases are reported in the literature with hyperplasia of the vascular malformation or disfiguring generalized gingival enlargement because of long-term phenytoin therapy [8]. In our case a well defined growth was present and histopathologically diagnosed as pyogenic granuloma, as per our knowledge, this is a rare case of SWS with bilateral port-wine stain having localized, well defined gingival growth suggestive of pyogenic granuloma.

Considering patients general condition, we need to modify the type of anesthesia. In our case, the excision was done under intravenous conscious sedation with propofol and N₂O-O₂ to reduce the patient's emotional stress. Periodontal ligament injection with 2% lignocaine containing 1:80,000U epinephrine was chosen for local anesthesia. Deep sedation requiring airway manipulation should be avoided because there are possible difficulties in airway maintenance. No change of antiepileptic drugs was suggested because of no enlarged gingiva and patient remained seizure free for many years.

Conclusion:

Each case of SWS is unique and exhibits the characterizing findings to varying degrees. While social stigma is lessened by the absence of PWS, the unknown natural course of the syndrome is still frustrating for parents and professionals treating the condition. So oral physicians should be aware of the signs and symptoms associated with SWS. Many times we may require consultation of neurophysician, dermatologist, a plastic surgeon, a neuropsychologist, pediatrician and genetic specialist, before attempting any dental procedures, to prevent complication and to give definitive treatment.

References:

1. Madaan V, Dewan V, Ramaswamy S, Sharma A. Behavioural manifestations of Sturge-Weber syndrome: A case report. *Prim Care Companion J of Clinical Psychiatry* 2006; 8:198-200.
2. Zaki SA, Lad V. Sturge-Weber syndrome with bilateral facial nevus and early cerebral calcification. *J Pediatr Neurosci* 2011; 6(2):114-115.
3. Sampaio Gc, Pereira Jrd, Crazal C, Sorbral Apv. Chronic apical periodontitis in patient with bilateral Sturge-Weber syndrome: report of a case. *Odontologia Clínico-Científica* 2008; 7(1):81-85
4. Khambete N, Risbud M, Kshar A. Sturge-Weber syndrome: A case report. *International Journal of Dental Clinics* 2011; 3(1):79-81
5. Mukhopadhyay S. Sturge-Weber syndrome: A case report. *J Indian Soc Pedod Prev Dent* 2008; 26 (Suppl1):S29-31.
6. Jing Z, Nan-yun LI, Xiao-jun Z, Jian-dong W, Heng-hui MA and Ru-song Z. Sturge-Weber syndrome: A case report and review of literatures. *Chinese Medical Journal* 2010; 123(1):117-121
7. Maria BN. Sturge-Weber Syndrome. In: Chapter 73: Current Management in Child Neurology. Third edition; 2005: 470-475
8. Hobson C, Foyaca-Sibat H, Hobson B, L de F Ibanez-Valdes. Sturge-Weber syndrome Type I "Plus": A Case Report. *The Internet Journal of Neurology* 2006; 5(2)
9. V Kumar, BK Prasad. Sturge Weber syndrome. *Katmandu University Medical Journal* 2004; 2(4)8:372-74.

*Author for Correspondence: Dr. Shantala Arunkumar, Department of Oral Medicine and Radiology, SDM College of Dental Sciences and Hospital, Sattur, Dharwad - 580009 (Karnataka) India.
Cell: 9481929790 Email: jinkashanti@gmail.com